



Dynamic smile visualization and quantification: Part 2. Smile analysis and treatment strategies

David M. Sarver, DMD, MS,^a and Marc B. Ackerman, DMD^b

Vestavia Hills, Ala, and Bryn Mawr, Pa

The “art of the smile” lies in the clinician’s ability to recognize the positive elements of beauty in each patient and then create a strategy to enhance the attributes that fall outside the parameters of the prevailing esthetic concept. New technologies have enhanced our ability to see our patients more dynamically and facilitated the quantification and communication of newer concepts of function and appearance. In a 2-part article, we present a comprehensive methodology for recording, assessing, and planning treatment of the smile in 4 dimensions. In part 1, we discussed the evolution of smile analysis and reviewed the dynamic records needed. In part 2, we review smile analysis and treatment strategies and present a brief case report. (*Am J Orthod Dentofacial Orthop* 2003;124:116-27)

Smile analysis is traditionally performed in 1 view—the frontal view.¹⁻⁹ But just as a person’s overall appearance is 3-dimensional (we see people frontally only a fraction of the time), so then should be the treatment of the smile. We have expanded smile analysis to include 3 other dimensions—oblique, sagittal, and over time—each having an important role in smile composition.

It is important to differentiate between the social smile and the enjoyment smile. The social smile is a voluntary smile a person uses in social settings or when posing for a photograph. When you are introduced to someone, your smile indicates that you are friendly and “pleased to meet” that person. The enjoyment smile^{1,10} is an involuntary smile and represents the emotion you are experiencing at that moment. The enjoyment smile therefore has many descriptors, such as laughing, wry, knowing, or insipid. The differing visual presentations reflect inner emotions and are mechanically governed by all the facial muscles of expression and the differential nuances of recruitment and use of these muscle sets. For example, in the knowing smile, the corners of the mouth are elevated slightly, and the eyebrows might also be raised. We call this a smile, but indeed the lips may not even be parted to expose the teeth. According

to both Darwin and Duchenne,^{10,11} we “smile with our eyes.”

When treating occlusal discrepancies, the orthodontist must have a repeatable position of tooth and jaw relationships to use as a reference point. In dentistry, the most accepted reference position in occlusion is the mandible placed in its most retruded contact position. In treating the smile, the social smile generally represents a repeatable smile.^{1,12} However, a social smile can mature and might not be consistent over time in some patients.

We have chosen the social smile as the representation from which we will analyze the smile in 4 dimensions: frontal, oblique, sagittal, and time-specific (Fig 1).

FRONTAL DIMENSION

To visualize and quantify the frontal smile, Ackerman and Ackerman^{1,13} developed a ratio, called the *smile index*, that describes the area framed by the vermilion borders of the lips during the social smile. The smile index is determined by dividing the inter-commissure width by the interlabial gap during smile (Fig 2). This ratio is helpful for comparing smiles among different patients or across time in 1 patient.

Frontally, we can visualize and quantify 2 major dimensions of the smile: vertical and transverse characteristics. The vertical characteristics of the smile are broadly categorized into 2 main features: those pertaining to incisor display and those pertaining to gingival display. The clinician must first ascertain whether the patient displays adequate gingival and dental architecture in the smile frame. If, for example, the patient shows less than 75% of the central incisor crowns at smile, tooth display is considered inadequate.⁶ The

^aAdjunct professor, Department of Orthodontics, University of North Carolina, Chapel Hill, USA; and private practice, Vestavia Hills, Ala.

^bClinical associate, Department of Orthodontics, University of Pennsylvania School of Dental Medicine, Philadelphia, USA; director of orthodontics, Division of Dentistry, Children’s Hospital of Philadelphia, USA; and private practice, Bryn Mawr, Pa.

Reprint requests to: David M. Sarver, DMD, MS, 1705 Vestavia Parkway, Vestavia Hills, AL 35216; e-mail, SarverD@aol.com.

Submitted, August 2002; revised and accepted, December 2002.

Copyright © 2003 by the American Association of Orthodontists.
0889-5406/2003/\$30.00 + 0

doi:10.1016/S0889-5406(03)00307-X

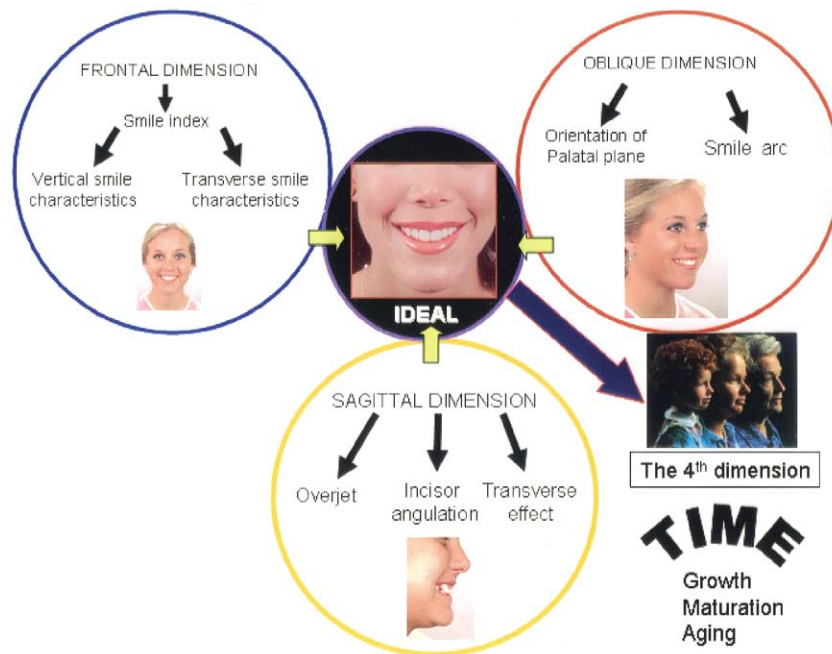


Fig 1. Three spatial views of systematic smile evaluation: frontal, oblique, and profile. Fourth dimension—maturation and aging—is critical in short- and long-term goal setting for treatment, retention, and maintenance.

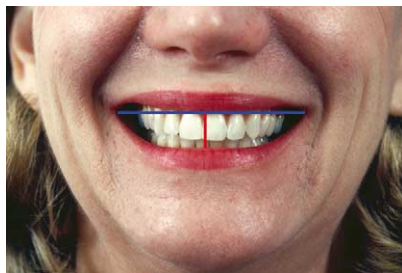

Fig 2. Smile index calculated by measuring intercommissure width and dividing by interlabial gap during smile. This patient has small smile index value with substantial incisor display on smile.

question then arises, what elements of the system are contributory? In this example, inadequate incisor display can be due to a combination of vertical maxillary deficiency, limited smile area (a large smile index), and short clinical crown height. If short clinical crown height is the primary contributor to the inadequate tooth display, we must then differentiate between a lack of tooth eruption (treated with observation), gingival encroachment (treated with cosmetic periodontics), and short incisors secondary to attrition (treated with cosmetic dentistry).

Other vertical smile characteristics are the relation-

ships between the incisal edges of the maxillary incisors and the lower lip, and between the gingival margins of the maxillary incisors and the upper lip. The gingival margins of the canines should be coincident with the upper lip and the lateral incisors positioned slightly inferior to the adjacent teeth. It is generally accepted that the gingival margins should be coincident with the upper lip in the social smile. However, this is very much a function of age, because children show more tooth at rest and have more gingival display on smile than do adults.

The 3 transverse characteristics of the smile in the frontal dimension are arch form, buccal corridor,^{3,14,15} and the transverse cant of the maxillary occlusal plane. Arch form plays a pivotal role in the transverse dimension of the smile. Recently, much attention has been focused on the use of broad, square arch forms in orthodontic treatment. When the arch form is narrow or collapsed, the smile may also appear narrow and therefore present inadequate transverse smile characteristics. An important consideration in widening a narrow arch form, particularly in adults, is the axial inclination of the buccal segments. Patients whose posterior teeth are already flared laterally are not good candidates for dental expansion. Patients with upright premolars and molars have more capacity for transverse expansion; this is true in adolescents, but it is particularly impor-



Fig 3. A, When arch form is narrow, transverse smile dimension might be affected because of insufficient transverse projection of both maxillary and mandibular arches, resulting in excessive buccal corridors. **B,** Orthodontic expansion and widening dramatically improved appearance of smile by decreasing size of buccal corridors and improving transverse smile dimension and smile presentation.

tant in adults because sutural expansion is less likely. Orthodontic expansion and widening of a collapsed arch form can dramatically improve the smile by decreasing the size of the buccal corridors and improving the transverse smile dimension (Fig 3). The transverse smile dimension (and the buccal corridor) is related to the lateral projection of the premolars and the molars into the buccal corridors. The wider the arch form in the premolar area, the greater the portion of the buccal corridor that is filled.

Arch expansion might fill out the transverse dimension of the smile, but 2 undesirable side effects could result, and careful observation is needed to avoid these, if possible. First, the buccal corridor can be obliterated, resulting in a denture-like smile. Second, when the anterior sweep of the maxillary arch is broadened (Fig 4, A), the smile arc may be flattened (Fig 4 B, C). This is particularly important today because of the trend toward broader arch forms. Although it may not be possible to avoid these undesirable aspects of expansion, the clinician must make a judgment in concert with the patient as to what tradeoffs are acceptable in the pursuit of the ideal smile.

The term *buccal corridor* was initially added to dental terminology by removable prosthodontics in the late 1950s.¹⁴ When setting denture teeth, they sought to recreate a natural dental presentation transversely. A molar-to-molar smile was considered a characteristic of

a poorly constructed denture. The buccal corridor is measured from the mesial line angle of the maxillary first premolars to the interior portion of the commissure of the lips. It is often represented by a ratio of the intercommissure width divided by the distance from first premolar to first premolar. As mentioned previously, the dimension of the buccal corridor is closely related to arch form and will be discussed later in relation to the sagittal position of the maxilla.

In adolescents, it is often desirable to increase arch width with rapid maxillary expansion to create space for nonextraction treatment. Figure 5, A shows a patient in whom the maxillary canines are blocked out and have insufficient room to erupt. On smile, she has moderately excessive negative space. In the overall treatment goal setting, expansion was required to create enough room for the canines. The final transverse smile dimension at age 14 years was significantly broader (Fig 5, B), and, depending on your taste, this much expansion might be considered excessive. However, with further maturation (don't forget the fourth dimension, time), the transverse smile characteristics fit nicely in her face, and her goal of a modeling career was not precluded (Fig 5, C).

The final transverse characteristic of the smile is the transverse cant of the maxillary occlusal plane. Transverse cant can be due to differential eruption and placement of the anterior teeth or skeletal asymmetry of

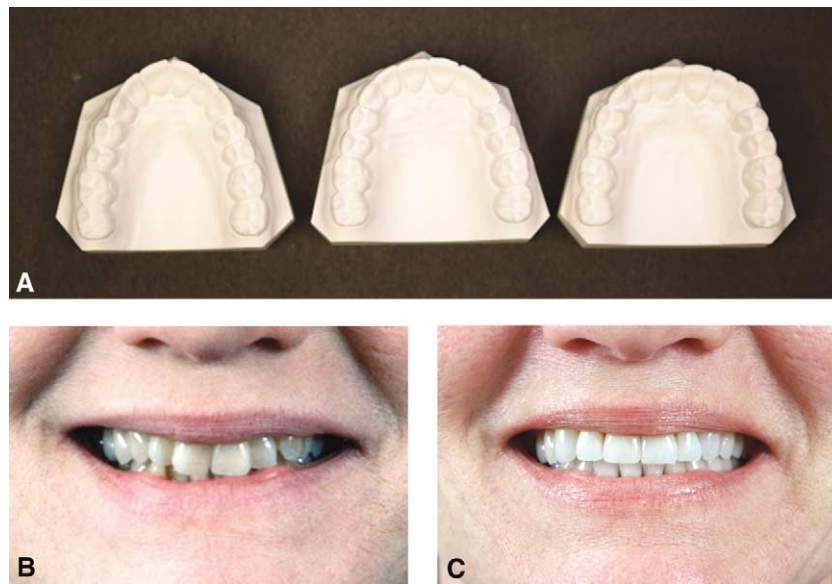


Fig 4. **A**, When anterior sweep of maxillary arch is broadened, smile arc may flatten. Trend for broader arch forms means clinician should beware of propensity for arch expansion to flatten smile arc and compensate with bracket placement, or at least consider esthetic tradeoffs in all smile dimensions. **B**, Patient with both dental crowding and inadequate transverse smile dimension. **C**, After arch expansion, buccal corridor was significantly diminished but smile arc had flattened.




Fig 5. **A**, Maxillary canines were blocked out with insufficient room to erupt. Rapid palatal expansion was recommended to increase maxillary arch length and avoid extractions. On smile, patient had moderately excessive negative space on smile and excellent incisor display and smile arc. **B**, Final transverse smile dimension at age 14 years was significantly broader, perhaps excessive. **C**, But with further maturation, transverse smile characteristics fit nicely in face.

the mandible resulting in a compensatory cant of the maxilla. Intraoral images, even mounted dental casts, do not adequately reflect the relationship of the maxilla

to the smile. Only frontal smile visualization permits the orthodontist to visualize any tooth-related or skeletal asymmetry transversely. The frontal smile photo-

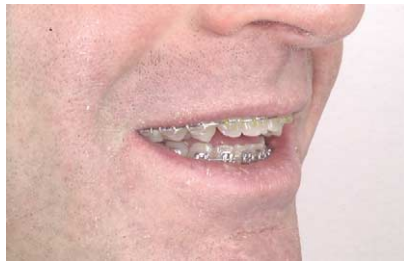

Fig 6. Oblique view allows clinician to see many smile characteristics not visible frontally. Patient has 50% maxillary incisor show on smile, and flatness of maxillary occlusal plane relative to lower lip curvature is apparent.

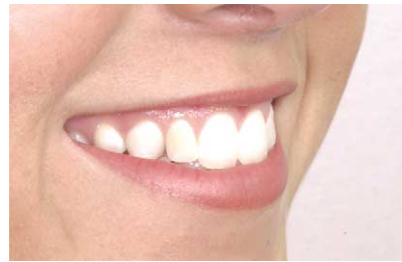

Fig 7. Oblique view expands definition of smile arc, from canine tip and maxillary incisor to lower lip curvature on smile, to now include molars and premolars. This smile arc is consonant with lower lip from molar to incisors.



Fig 8. A, In patients with sagittal skeletal discrepancies (in this case, Class III maxillary insufficiency), the frontal smile can appear esthetic. **B,** Oblique view reveals underlying skeletal pattern and dental compensation.

graph, either full face or close-up, is a much better indicator of transverse dental asymmetry than the frontal retractor view. With good visualization and documentation of tooth-lip relationships, the orthodontist can make appropriate adaptations in appliance placement or make a decision as to the need for differential growth or dental eruption modification of the maxilla in the adolescent or surgical correction in the adult.

Smile asymmetry may also be due to soft tissue considerations, such as an asymmetric smile curtain. In the asymmetric smile curtain, there is a differential elevation of the upper lip during smile, which gives the illusion of a transverse cant to the maxilla. This smile

characteristic emphasizes the importance of direct clinical examination in treatment planning, because this soft tissue animation is not visible in a frontal radiograph or reflected in study models. It is poorly documented in static photographic images and is documented best in digital video clips.

OBLIQUE DIMENSION

The oblique view of the smile shows characteristics of the smile not obtainable on the frontal view and certainly not obtainable through any cephalometric analysis. The palatal plane can be canted anteroposteriorly in a number of orientations. In the most desirable orientation, the occlusal plane is consonant with the



Fig 9. A, Patient with Class III malocclusion secondary to maxillary deficiency. Some aspects of vertical maxillary deficiency are present, including 50% of maxillary incisor show on smile. Transverse smile dimension characterized by excessive buccal corridors. **B,** Maxillary downgraft resulted in increased vertical incisor display. Maxillary advancement improved buccal corridor on smile.

curvature of the lower lip on smile (smile arc, to be discussed next). Deviations from this orientation include a downward cant of the posterior maxilla, upward cant of the anterior maxilla, or variations of both.¹⁶ In the initial examination and diagnostic phase of treatment, it is important to visualize the occlusal plane in its relationship to the lower lip. Figure 6 illustrates an open bite in preparation for maxillary surgery to close an anterior open bite. Whether the posterior maxilla should be impacted or the anterior maxilla should come down depends on the amount of incisor show at rest and on smile and the smile arc relationship, and this is best visualized in the oblique view.

The *smile arc* is defined as the relationship of the curvature of the incisal edges of the maxillary incisors, canines, premolars, and molars to the curvature of the lower lip in the posed social smile.^{1,17} In the ideal smile arc, the curvature of the maxillary incisal edge is parallel to the curvature of the lower lip upon smile; *consonant* is used to describe this parallel relationship. A *nonconsonant* or flat smile arc is characterized by a flatter maxillary incisal curvature than the curvature of the lower lip on smile. Early definitions of the smile arc were limited to the curvature of the canines and the incisors to the lower lip on smile, because smile evaluation was made on direct frontal view. The visualization of the complete smile arc afforded by the oblique view expands the definition of the smile arc to

include the molars and the premolars, as can be seen in Figure 7.

SAGITTAL DIMENSION

The 2 characteristics of the smile that are best visualized in the sagittal dimension are overjet and incisor angulation. Excessive positive overjet is one of the dental traits most recognizable to the lay person. Unflattering terms, such as “Andy Gump” and “Bucky Beaver,” have been attached to children unfortunate enough to have inherited this dentoskeletal pattern. How overjet is corrected orthodontically involves macro-elements, such as jaw patterns, and soft tissue elements, such as nasal projection. In terms of the smile, excessive positive overjet is not as readily perceived in the frontal dimension as it is in the sagittal dimension. For example, in many Class II patterns, the smile is esthetic frontally, but the problem is obvious when observed from the side. In Class III patterns, the same may be true: the frontal smile looks esthetic (Fig 8, A), but the oblique or sagittal view shows the underlying skeletal pattern and dental compensation (Fig 8, B). The patient and the parents must decide with the clinician whether this is an acceptable outcome in terms of total appearance and oblique smile characteristics.

The amount of anterior maxillary projection also greatly influences smile characteristics in the frontal

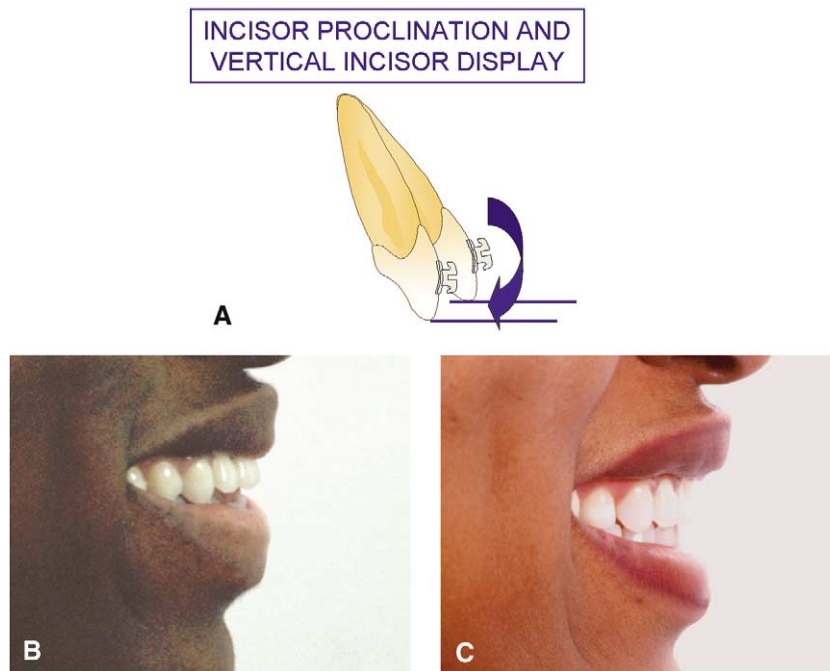


Fig 10. **A**, Proclination of maxillary incisors can affect incisor display at rest and on smile. Flared maxillary incisors tend to reduce incisor display, and upright maxillary incisors tend to increase incisor display. Sagittal views show **B**, flare of maxillary incisors and, **C**, increased incisor display after incisors have been uprighted.

view, even in terms of transverse smile dimension. When the maxilla is retrusive, the wider portion of the dental arch is positioned more posteriorly relative to the anterior oral commissure. This creates the illusion of greater buccal corridor in the frontal dimension. The patient in Figure 9, *A*, had a Class III malocclusion due to maxillary deficiency, both vertically (characterized by only 50% of maxillary incisor show on smile) and anteroposteriorly (as evidenced by the flatness of the profile). After orthodontic decompensation, the surgical plan was designed to advance the maxilla, rotating it clockwise to increase the amount of incisor show at rest and on smile. This occlusal plane rotation not only improves the incisal display but also increases midfacial projection and diminishes mandibular projection. The smile was greatly enhanced by the increased vertical anterior tooth display (Fig 9, *B*), but the transverse smile dimension was also greatly improved. How was the negative space on smile reduced when there was no maxillary expansion? The answer lies in the 3-dimensional effect of the maxillary advancement. As the maxilla came forward into the buccal corridor, the negative space was reduced by the wider portion of the maxilla coming forward into the static intercommissure width. The advancement of the maxilla results

in a wider portion of the maxilla being placed into the buccal corridor, reducing “negative space.” Transverse smile dimension, therefore, is a function of both arch width and anteroposterior position of the maxillary and mandibular arches. In other words, bringing the wider portion of the maxilla forward simply fills up the negative space.

Incisor proclination (placed here in the sagittal dimension) can also have a dramatic effect on incisor display. In simple terms, flared maxillary incisors tend to reduce incisor display, and upright maxillary incisors tend to increase it (Fig 10, *A*). A good example is the patient in Figure 10, *B*. This patient had an anterior open bite secondary to extreme anterior proclination of the maxillary and mandibular incisors. The sagittal view of the smile shows the flare of the maxillary incisors; this resulted in diminished incisor show from both the sagittal and the frontal views. The treatment plan consisted of extracting the first premolars and retracting the incisors. Care was taken to retract the incisors on round wire so that the crowns rotated around the bracket slot into a more inferior position. This movement closed the anterior open bite and increased incisor display as the teeth were retracted. The profile view of the smile demonstrates the im-

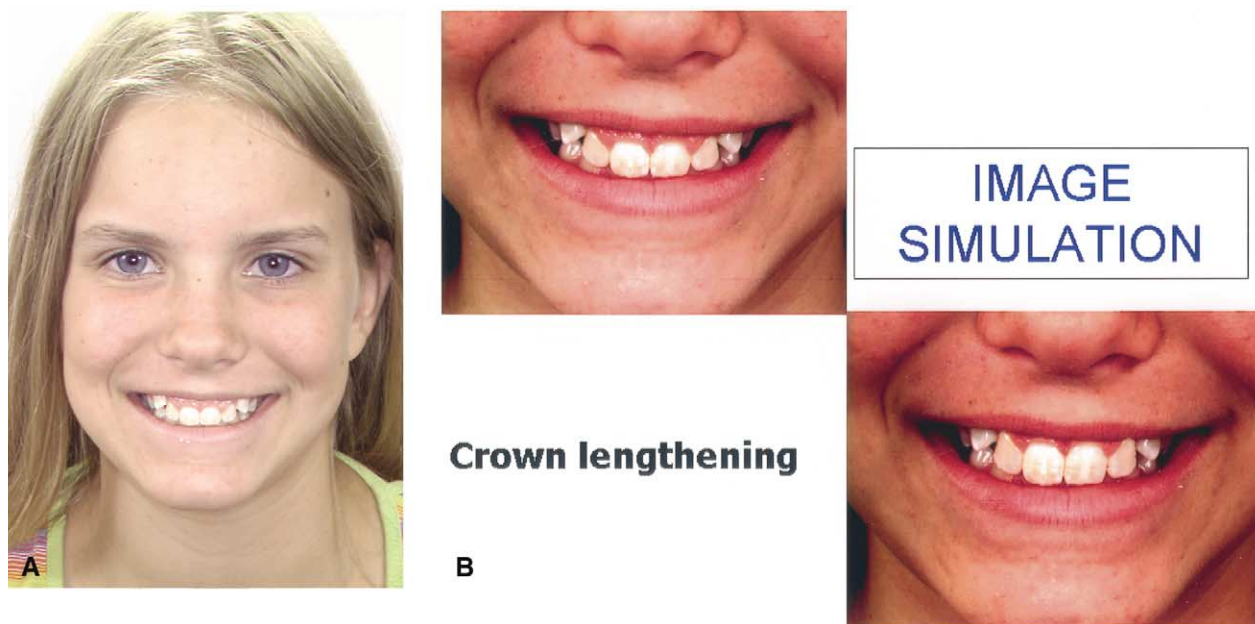

Fig 11. A, Patient with crowding of maxillary arch and partially blocked-out canines. Smile characterized by excessive gingival display. Alignment of posterior teeth and incisors consonant with lower lip on smile—smile arc. Incisor crown height was 8 mm. **B, C,** Computer simulation of treatment plan, keeping incisal edges in place and moving gingival margins superiorly. Orthodontic intrusion of incisors to reduce gingival display would result in flattening of smile arc.

proved angulation and vertical position of the maxillary incisors (Fig 10, C).

THE FOURTH DIMENSION: TIME

The growth, maturation, and aging of the perioral soft tissues have a profound effect on the appearance of both the resting and smiling presentations. Orthodontic patients can be categorized as preadolescent, adolescent, and adult. In preadolescent patients, the facial soft tissues are still in a growth phase, and treatment decisions pertaining to the relative facial divergence (posteriorly or anteriorly) at profile and frontal facial soft tissue topography must take this into account. Adolescent patients, or those at the point of pubertal onset, have experienced the maximum velocity in the growth of the skeletal subunits and have roughly achieved their facial soft tissue “look.” In adults, nuances in the aging of perioral and facial soft tissues become increasingly important. We know from orthodontic cephalometric research that, on average, profiles flatten over time. Whether this is mostly related to ptosis of the soft tissues or resorptive fields in the hard tissues of the midface is still debated, but it is nevertheless a consequence of getting older.

In a direct measurement study of more than 3500 subjects, Dickens et al¹⁸ studied the changes in phil-

trum height and commissure height in patients from age 6 years to their 40s and the relationship to the smile. These data demonstrate the lengthening of the philtrum and commissure, with the rate of philtrum lengthening greater than that of the commissures. This would explain the flattening of the “M” characteristics of the vermilion border of the upper lip in the youthful lip. Lengthening of the philtrum and the commissure with age is reflected in the curves demonstrating reduced tooth display at rest and gingival display.

The effects of maturation and aging on the soft tissues can be summarized as (1) lengthening of the resting philtrum and commissure heights, (2) decrease in turgor (or tissue “fleshiness”), (3) decrease in incisor display at rest, (4) decrease in incisor display during smile, and (5) decrease in gingival display during smile.

PROBLEM-ORIENTED TREATMENT PLANNING AND IDENTIFYING POSITIVE ATTRIBUTES

In problem-oriented treatment planning, we identify the problems that require improvement or correction and focus primarily on correcting those problems. We propose that the next fundamental component in treatment planning in the contemporary orthodontic analysis should include identifying and quantifying the positive aspects of the patient’s esthetic arrangement.

In this approach to problem-oriented treatment planning, we clearly want to fix what is wrong, but not at the expense of what is right about a patient's esthetic presentation.

The following example will illustrate this principle. The patient in Figure 11, A, had crowding of the maxillary arch with partially blocked-out canines. Her smile is characterized by excessive gingival display that was judged to be an esthetic problem. In our systematic evaluation, the etiology of the gummy smile was due primarily to the short clinical crown height of 8 mm. Thus, our main problems (as related to the smile) were short incisor heights and excessive gingival display on smile. That is the problem list, but what is right about the smile? What attributes of this smile do we want to preserve? Her maxillary occlusal arc is consonant with the lower lip curvature on smile; thus her smile arc is ideal. One option to reduce the gumminess of the smile is intrusion of the maxillary incisors, but this would result in an undesirable flattening of her smile arc. When we visualized her smile with computer imaging and simulated cosmetic periodontal crown lengthening (Fig 11, B), the treatment plan became clear. Computer imaging helps the clinician to see the plan and cogently present treatment options to the patient and family, as well as to communicate with other professionals involved in the care of the patient. The subsequent treatment strategy is (1) maintain the incisal edges in their current vertical position, (2) extrude the maxillary canines to level the arch, and (3) finish with periodontal crown lengthening. Bracket placement was critical to our orthodontic approach because we wanted to level the anterior and posterior segments in a continuous archwire, bypassing the canines. In this way, we protect the smile arc, identified in our original examination and diagnosis as a good feature to be maintained. When a full-dimension wire was reached, a light auxiliary thermoelastic wire was threaded from the auxiliary tube on the maxillary molars and ligated to the anterior archwire, so that the canines could be extruded without a subsequent intrusion of the maxillary incisors.

One of the most accepted attributes of an esthetically pleasing smile is the smile arc. The anatomic contributions to the smile arc are visualized best in the oblique dimension, but the factors influencing it are found in all 3 dimensions. When attempting to alter the smile arc, the following strategies can be used:

1. Treating the occlusal plane in preadolescents with a growth modification appliance can be advantageous. Examples of these appliances include vertically directed headgear, vertical control functional appliances, and the Herbst appliance.
2. In late adolescent and adult patients, surgical modification of the maxillary occlusal plane is often indicated. Maxillary advancement coupled with clockwise occlusal plane rotation will harmonize the positions of the maxillary incisal edges with the lower lip and improve the buccal corridors by bringing the wider portion of the maxillary arch forward.
3. Bracket placement is also crucial to either maintaining or modifying the smile arc. Conventional straight-wire prescriptions call for a 0.5-mm difference in the incisal-edge-to-bracket-slot distance between maxillary central and lateral incisors. It has been our experience that a distance of 1 to 1.5 mm between lateral and central incisor bracket slots and the incisal edges is needed to preserve or create consonant smile arcs. This helps to superiorly position the lateral incisors and preserve the gradual sweep of the smile arc.
4. Cosmetic porcelain laminates or composite bonding can also play a role in enhancing the smile arc. Orthodontic treatment planning must consider tooth morphology, and multidisciplinary care might be indicated. Figure 12, A, demonstrates how the oblique smile close-up helps the orthodontist to visualize where to place the teeth as the gingival margins relate to the upper lip on smile and as the position of the incisal edges relates to the lower lip on smile, so that the porcelain laminates create a harmonious relationship on smile (Fig 12, B).
5. Finally, enamel odontoplasty can be used to conservatively reshape the incisal edges of the maxillary anterior teeth during orthodontic finishing.

CASE ILLUSTRATION

This 45-year-old man was referred by his dentist after he had finally exfoliated his maxillary right deciduous canine (Fig 13, A). The dentist was evaluating him for restoration of the missing tooth but, because of the malocclusion, referred him for a preprosthodontic orthodontic consultation. He had Class I posterior relationships but also an edge-to-edge incisal relationship that had resulted in attrition of both the maxillary and mandibular anterior teeth. His overall dental condition reflected a remarkable amount of attrition and wear.

Our systematic evaluation yielded the following information.

Resting tooth-lip relationships included a philtrum height of 28 mm, commissure height of 30 mm, and maxillary incisor display at rest of 1 mm. Dynamic

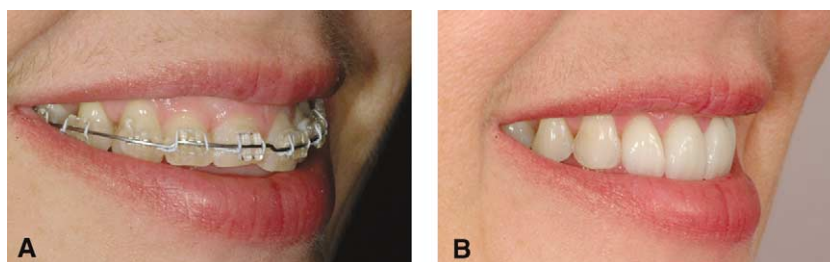


Fig 12. **A**, Close-up image of oblique smile helps clinician visualize placement of teeth as gingival margins relate to upper lip on smile and as incisal edges relate to lower lip on smile. **B**, Coordinating smile arc goals, specific bracket placement, and final laminates result in outstanding smile.

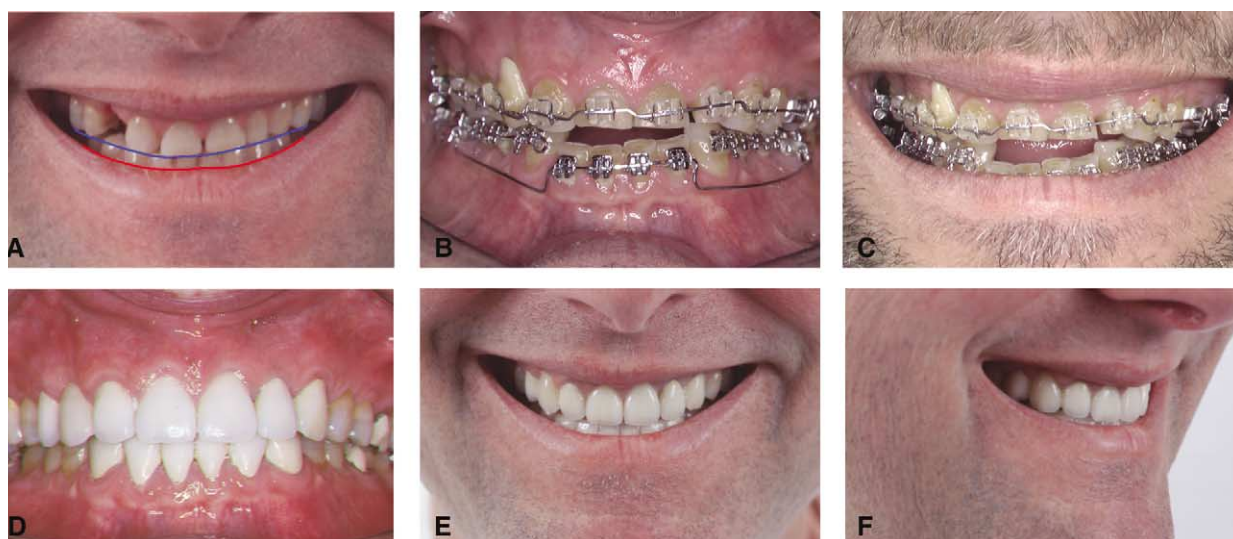


Fig 13. Maxillary right lateral incisor was congenitally missing, and retained maxillary right deciduous canine had just been lost. Maxillary right canine was in lateral incisor position. Note severe attrition of maxillary anterior teeth and variable gingival heights relative to each other and the upper lip on smile. Despite attrition, smile arc was consonant, with cusp tips and incisal edges parallel to lower lip. **B**, Significant intrusion of mandibular incisors needed to provide vertical clearance for restoration and enough room for ideal smile arc after restoration of maxillary incisors. **C**, Bracket placement and differential intrusion of maxillary incisors resulted in coordination of gingival margins with upper lip on smile, and coordination to each other. **D**, After final full coverage restoration of maxillary and mandibular dentitions. **E**, Targets of dynamic smile were attained, including alignment of maxillary incisor gingival margins with upper lip on smile and incisal edges, canine tips, and premolar tips in a consonant relationship to lower lip on smile. **F**, Oblique view shows successful alignment of smile arc and result of sufficient mandibular incisor intrusion to reach treatment goals.

tooth-lip relationships (vertical dimensions of the smile) included 100% maxillary anterior tooth display, no excessive gingival display on smile, and varied crown heights due to the attrition. The maxillary right lateral incisor was congenitally missing, and the permanent canine had drifted anteriorly to fill the lateral position. The right deciduous canine, which had re-

cently exfoliated, had filled in the canine space. The crowns were measured individually so that we could plan vertical position of the gingival margins appropriately. The right canine was 8 mm, the right central incisor was 7 mm, the left central incisor was 6.5 mm, and the left lateral incisor was -7 mm.

Frontally, no transverse cant of the maxilla was

noted, although some slight asymmetry of the smile appeared secondary to the varied anterior tooth heights. Transverse smile dimension as it related to the buccal corridors was judged to be quite good.

No anteroposterior cant was noted in the oblique and sagittal views, and the smile arc was consonant. Although the anterior teeth were quite short, they were, with the premolars and canines, parallel to the curvature of the lower lip on smile.

Finally, we assessed the characteristics of the patient's smile over time—the fourth dimension. We calculated that the patient had experienced 40% attrition of his maxillary central incisors and 50% attrition of the mandibular incisors. This resulted in no incisor show at rest and diminished incisor show in speech. Gradual diminishment of incisor display is a primary characteristic of dental aging. Because of the patient's lack of overjet, the functional goals of treatment were to orthodontically advance the maxillary incisors so that incisor crown length could be added. As a secondary goal, we thought it was necessary to intrude the incisors to open the bite so that restoring the lost incisor length would not deepen the bite.

Goals of treatment

Coordinating the maxillary incisor gingival margins with the upper lip on smile was a goal of treatment. Many orthodontists still use arbitrary standards for bracket placement; these might be adequate but do not take into account the relationship of the anterior teeth to the animated characteristics of the smile. These include instrument-guided placement of central incisor brackets 4 mm above the incisal edge of the central incisors, 3.5 mm above the cusp tips of the lateral incisors, and 4.5 mm above the tips of the canines and in the center third of the tooth vertically and horizontally, per straight-wire prescription.

This patient presented a different challenge in placing the bracket and its slot, because the goal was not to align the incisal edges but to align the gingival margins. This includes aligning the gingival margins to each other in terms of canine, lateral, and central incisor heights, and the gingival margins to the upper lip on smile. Because the goal was to idealize the gingival margins by differential intrusion or extrusion relative to each other and the lip, the brackets were placed with the main frame of reference being the distance of the slot from the gingival margin, not the incisal edges. Intruding the mandibular incisors would open the bite. This was required to provide room for vertical restoration of both the maxillary and mandibular incisors, so significant intrusion was indicated. How much intrusion would be required? The parameters for how much

interincisor distance was needed included (1) how long the maxillary incisors needed to be to attain desired length, (2) how much length was needed to improve maxillary incisor display at rest, (3) how much length was needed to facilitate mandibular incisor restoration, and (4) how much length was needed in the maxillary incisors to attain the desired smile arc relationship. Finally, the dentition would be restored, including replacement of the missing tooth.

Evaluation of the smile and synchronization of all the parameters of smile analysis

Figure 13, A, shows a close-up of the smiling relationship. The gingival margins of the maxillary incisors reasonably approximated the curvature of the upper lip on smile, but the gingival margins were not in the ideal esthetic position relative to the upper lip or each other. Specifically, the maxillary right canine was longer than the central incisor, and the lateral margin was equal to the central gingival height. The curvature of the premolars and anterior teeth closely approximated the curvature of the lower lip on smile (smile arc), but the teeth were much shorter, and the curvature of the maxillary incisors fell short of the curvature of the lower lip.

The overall idea was, of course, to restore the dentition, but the edge-to-edge incisal relationship was a problem, and adding crown length would tend to create an impinging deep bite. The interdisciplinary plan was as follows:

Maxillary bracket positioning. In most bracket placement schemes, the frame of reference is either the center of the tooth (in most straight-wire schemes) or a uniform distance from the incisal edge. In this case, however, we were not treating a normal tooth-gingiva-lip relationship. Our frame of reference for maxillary bracket placement was not the incisal edges, but the gingival margins. It was also necessary to place the brackets so that the gingival heights of the central incisors were slightly higher than the lateral incisors, and the canines slightly higher than the central incisors.

Mandibular bracket positioning. The mandibular incisor brackets were placed as incisally as possible. Because of the attrition, limited tooth structure was available for bonding, but the bracket ended up in the center of the tooth.

Bioprogressive utility arches. Maxillary and mandibular bioprogressive-type utility arches were placed, resulting in intrusion of the mandibular incisors approximately 6 mm (Fig 13, B). Careful placement of the maxillary brackets, related to the gingival margins rather than the incisal edges, resulted in good alignment of the gingival margins to the upper lip on smile (Fig

13, C). Typically at this point, the dentist takes a facebow mounting and performs a diagnostic wax-up to determine whether the teeth are in the correct position for restoration. Sometimes, we even recommend the fabrication of a processed temporary overlay for the patient to place over the incisors so that the patient can see and approve the resting and smiling incisor relationships. Some space was created between the incisors so that the crowns could be fabricated with proper emergence profiles. As the incisors were worn vertically, they drifted together, and the contact point moved more apically. Without recreating space, the restoration of the incisors would have to be narrower than ideal, with inappropriately long connectors. The final restorative outcome is shown in Figure 13, D. An important feature of this case was the adequate intrusion of the mandibular incisors to permit adequate incisor display at rest and on smile. The close-up of the smile (Fig 13, E) illustrates placement of the gingival margins to the upper lip on smile, and the oblique close-up smile also demonstrates the excellent smile arc characteristics (Fig 13, F).

CONCLUSIONS

In this 2-part article, we have discussed a comprehensive methodology for recording, assessing, and planning treatment of the smile in 4 dimensions. Orthodontic history, beginning with Angle and Wuerpel, has taught us that the “art of the smile” lies in the clinician’s ability to recognize the positive elements of beauty in each patient and then create a strategy to enhance the attributes that fall outside the parameters of the prevailing esthetic concept. The difference between contemporary orthodontic practice and that of our predecessors is that we now can dynamically visualize and quantify our patients’ smiles. Orthodontic diagnosis has, in a certain sense, come full circle. But the focus on the lineaments of the smile is not a step back in time; rather, it represents a reemphasis of the importance of physical diagnosis and the appreciation of the soft tissues that both drive our treatment planning and limit the treatment response. New technology simply enhances our ability to see our patients more

dynamically and facilitates the quantification and communication of newer concepts of function and appearance.

REFERENCES

1. Ackerman JL, Ackerman MB, Brensinger CM, Landis JR. A morphometric analysis of the posed smile. *Clin Orthod Res* 1998;1:2-11.
2. Ackerman MB, Ackerman JL. Smile analysis and design in the digital era. *J Clin Orthod* 2002;36:221-36.
3. Hulsey CM. An esthetic evaluation of lip-teeth relationships present in the smile. *Am J Orthod* 1970;57:132-44.
4. Mackley RJ. An evaluation of smiles before and after orthodontic treatment. *Angle Orthod* 1993;63:183-90.
5. Miller CJ. The smile line as a guide to anterior esthetics. *Dent Clin North Am* 1989;33:157-64.
6. Morley J, Eubank J. Macroesthetic elements of smile design. *J Am Dent Assoc* 2001;132:39-45.
7. Phillips E. The anatomy of a smile. *Oral Health* 1996;7-13.
8. Phillips E. The classification of smile patterns. *J Can Dent Assoc* 1999;65:252-4.
9. Tjan A, Miller G, The J. Some esthetic factors in a smile. *J Prosthet Dent* 1984;51:24-8.
10. Duchenne de Boulogne GM. The mechanism of human facial expression. Cambridge, United Kingdom: Cambridge University Press; 1990.
11. Darwin C. The expression of emotions in man and animals. Des Moines, Iowa: Meredith Publishing; 1882.
12. Rigsbee OH, Sperry TP, BeGole EA. The influence of facial animation on smile characteristics. *Int J Adult Orthod Orthognath Surg* 1988;3:233-9.
13. Ackerman MB. Digital video as a clinical tool in orthodontics: dynamic smile design in diagnosis and treatment planning. In: 29th Annual Moyer’s Symposium. Vol 40. Ann Arbor: University of Michigan Department of Orthodontics; 2003.
14. Frush JO, Fisher RD. The dynesthetic interpretation of the dentogenic concept. *J Prosthet Dent* 1958;8:558-81.
15. Lombardi RE. The principles of visual perception and their clinical application to denture esthetics. *J Prosthet Dent* 1973; 29:358-82.
16. Burstone CJ, Marcotte MR. The treatment occlusal plane. In: Problem solving in orthodontics: goal-oriented treatment strategies. Chicago: Quintessence Publishing; 2000. p. 31-50.
17. Sarver DM. The importance of incisor positioning in the esthetic smile: the smile arc. *Am J Orthod Dentofacial Orthop* 2001;120: 98-111.
18. Dickins S, Sarver DM, Proffit WR. The dynamics of the maxillary incisor and the upper lip: a cross-sectional study of resting and smile hard tissue characteristics. *World J Orthod* 2002;3:313-20.